

# Arthroscopic Rotator Cuff Repair

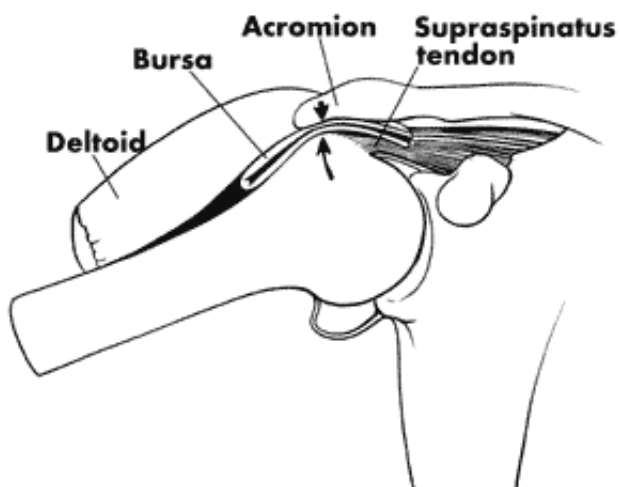
## Anatomy

The term "Rotator Cuff" describes the group of muscles and their tendons in the shoulder that helps control shoulder joint motion. The supraspinatus is at the top (superior) of the shoulder, the subscapularis is anterior (front), and the infraspinatus and teres minor are posterior (behind). These muscles insert or attach to the humeral head by way of their tendons. The tendons fuse together in a strong band of tissue giving rise to the term "cuff." Although each muscle acting alone may produce an isolated rotational movement of the shoulder, the role they play together is to help keep the humeral head (ball) centered within the glenoid (socket) as the powerful deltoid and other larger shoulder muscles act to lift the arm overhead.

Above the rotator cuff is a bony projection from the scapula (shoulder blade) called the acromion. The acromion forms the "ceiling" of the shoulder, serves as the point of origin for the deltoid muscle, and joins the clavicle (collarbone) to form the acromioclavicular (a/c) joint. Between the rotator cuff tendons and the acromion is a protective fluid-filled sack called a "bursa". With normal upper arm elevation there is some contact between the rotator cuff, the bursa, and the acromion.

## Pathology

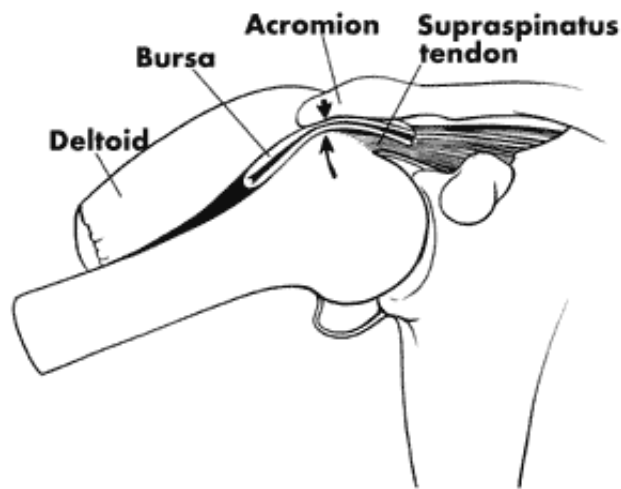
Rotator cuff pathology can be caused by extrinsic (outside) or intrinsic (from within) causes. Extrinsic examples include a traumatic tear in the tendon(s) from a fall or accident at work or at home. Overuse injuries from repetitive lifting, pushing, pulling, or throwing are also extrinsic in nature. Intrinsic factors include poor blood supply, normal wear and tear or degeneration with aging, and calcific invasion of the tendon(s).



Rotator cuff "tendonitis" or "tendonosis" are the terms used to describe irritation of the tendon(s) either from excessive pressure on the acromion or less commonly from intrinsic tendon pathology. Irritation of the adjacent bursa is known as subdeltoid or subacromial "bursitis." Repetitive overhead activities resulting in irritation of the tendon(s) and bursa from repeated contact with the undersurface of the acromion which may develop a bone spur and dig into the cuff is called "Impingement Syndrome."

Rotator cuff dysfunction is typically a continuum of pathology ranging from tendonitis and bursitis to

partial tearing, to a complete tear in one or more of the tendons. Although the earlier stages may resolve with conservative care, actual tearing of the tendon can be more problematic. These tears most commonly occur at the junction where the tendon joins the bone. Because this area has a relatively poor blood supply, injury to the tendon here is very unlikely to actually heal. Additionally, the constant resting tension in the muscle-tendon unit pulls any detached fibers away from the bone, preventing their reattachment. Finally, joint fluid from within the shoulder may seep into the tear gap preventing the normal healing processes from occurring.

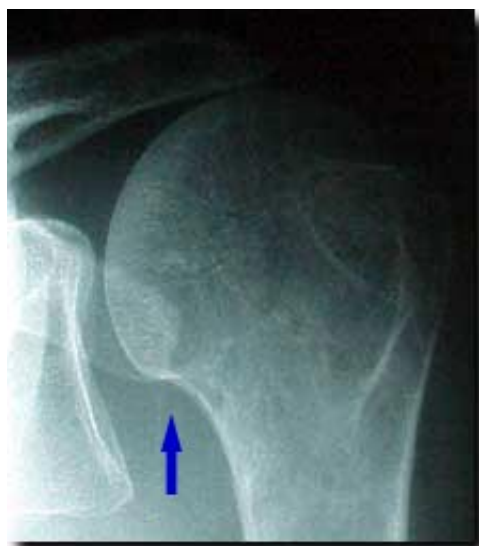

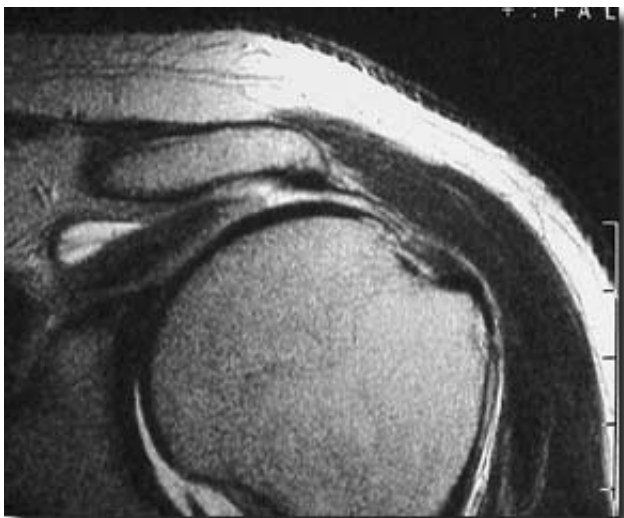## Diagnosis

Patients with rotator cuff pathology commonly present with an activity related dull ache in their upper lateral (outer) arm and shoulder. Above shoulder level activity is usually most difficult. Many people have little to no discomfort with below shoulder level activities such as golf, bowling, gardening, writing or typing, etc. Conversely, tennis, baseball/softball, basketball, swimming, painting, etc. will be more problematic.

Pain in the shoulder may extend down as far as the elbow, but not usually beyond. Neck pain on the same side may develop later as a result of using the scapular elevators excessively to compensate for abnormal glenohumeral motion. These scapular elevators, such as the trapezius originate from the cervical spine and can cause pain in the posterior neck and well as occipital (low) headaches. Patients may also experience snapping or cracking within the shoulder, pain at night, difficulty lying on the shoulder, and difficulty getting dressed. Late findings include weakness and loss of shoulder motion.

X-rays will not show the soft tissue of the rotator cuff, but they will reveal any evidence of arthritis, spurs within the shoulder, loose bodies, fractures from a related fall, abnormal displacement of the humerus out of the glenoid, and congenital (birth) related problems. Therefore, good quality x-rays are a must in the proper evaluation of the shoulder.





Magnetic Resonance Imaging or MRI has allowed visualization of the soft tissues of the body, including the rotator cuff. An MRI can reveal tendonitis, partial tearing, and complete tears of the rotator cuff. While an MRI is usually not required to diagnose a torn rotator cuff, it can be very helpful to determine which tendons are torn, how large the tear is, the degree of tendon retraction, the extent of muscle belly atrophy (shrinkage), and any coexisting problems.

## Conservative Treatment

Many rotator cuff tears do not require surgery. Conservative treatment of rotator cuff disease classically includes rest, activity modification, nonsteroidal anti-inflammatory medications, and physical therapy. Therapy may include heat, cold, ultrasound, electrical stimulation, massage and other modalities, but the hallmark of an effective rotator cuff rehabilitation program is therapeutic exercise. Stretching of the posterior joint capsule can help the tendency of the humeral head to shift superiorly toward the acromion with forward elevation. Strengthening of the remaining rotator cuff through resistance exercises can again help contain the humeral head within the glenoid and avoid undue pressure up on the acromion. Finally, muscle re-education to normalize the mechanics of shoulder motion can help return the patient to his or her full function.

In patients who fail to improve with initial conservative therapy, there may be a role for judicious use of corticosteroid ("cortisone") injection therapy in the bursa above the tendon. The mechanism of how this technique may be helpful is not completely clear, but it may reduce bursal and tendon irritation and swelling. The cortisone does not just "mask" the problem, but helps break the cycle of pain, swelling, weakness, and continued impingement. Injection therapy may then help reduce pain and impingement and allow the individual to continue to work on rotator cuff strengthening. Current recommendations are that a maximum of 3 cortisone injections should be used per shoulder. There is some evidence in laboratory research that more than 3 cortisone injections around an otherwise healthy tendon may result in considerable weakening of the tendon and even rupture.

## Surgical Treatment

Patients with more advanced rotator cuff disease or a more significant injury may fail efforts at conservative therapy. If the patient's quality of life is significantly impacted by the shoulder dysfunction, then consideration of surgical intervention is certainly reasonable. In some cases simple debridement of a frayed or partially torn cuff tendon along with smoothing of the undersurface of the acromion (acromioplasty) above the tendon may be all that is needed. More significant partial tearing (more than 50% of the tendon thickness) and complete tears require reattachment of the tendon ends back to the humeral head.

Very extensive rotator cuff repair is most commonly done by arthroscopic surgical procedures, which typically requires a 3 small incisions at the top of the shoulder. This technique will usually be done on an outpatient basis, or occasionally as an inpatient surgery. Arthroscopic techniques for rotator cuff repair were developed over 20 years ago and have been constantly improved. This is an extremely difficult approach for the surgeon to initially learn, but once mastered, can be quite rewarding for both doctor and patient. Unlike the open technique, the incisions used for an arthroscopic repair only the size of a shirt buttonhole. There may be 3 to 4 of these very small incisions, and early indications are, as might be expected, that patients have much less postoperative pain and require less prescription pain medication as a result. As a result, this is usually done as an outpatient procedure. Several studies have shown that the long-term results are as good as the "gold standard" open approach.

## Post Operative Rehabilitation

Whether done open or arthroscopically, rotator cuff repair is a major operation that requires considerable rehabilitation. Several rehabilitation protocols for rotator cuff repair are available and are based on the size of the tear and repair. The shoulder is typically protected in a sling for 3-4 weeks, although some gentle passive motion is typically begun almost immediately. If the rotator cuff tissue was of good quality the patient can be started on a CPM (continuous passive motion machine) which speeds up the restoration of motion. It takes 12 weeks for the tendon to begin to heal down to the bone, and that the attachment continues strengthen for 2 years. Despite the prolonged healing course, patients can very often begin light computer work or writing in 1 to 2 weeks, lift the arm overhead 2 months after surgery, participate in golf, fishing, and other less strenuous activities at 4 months, and return to full sports and work participation at 5 to 6 months. Long term studies have revealed 80 to 95 percent good to excellent results for rotator cuff repair done open or arthroscopically. Patient satisfaction rates are just as high. In the majority of these studies, over 90% of patients agreed that in respect they would have the surgery again if needed. Unfortunately patients with worker's compensation cases or other litigation related to the shoulder injury have not enjoyed the same success rates. Good to excellent results in these patients may be as low as 65 to 75 percent, yet they are just as likely to indicate that they would have the surgery again if necessary. A well-motivated patient combined with a well-done repair and a comprehensive rehabilitation program, typically results in a satisfied patient who is able to return to his or her normal activities of daily living with little to no compromise.